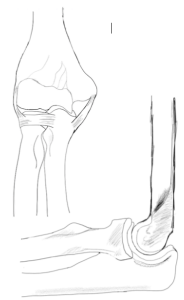


MATTHEW J. DUBIEL M.D. SHOULDER AND ELBOW SURGERY

WWW.MDUBIELMD.COM



CTS-6 Evaluation Tool

The Value Added by Electrodiagnostic Testing in the Diagnosis of Carpal Tunnel Syndrome *Brent Graham J Bone*
Joint Surg Am. 2008;90:2587-2593

Symptoms and History

- 1. Numbness predominantly or exclusively in the median nerve territory** _____ (3.5)
Sensory symptoms are mostly in the thumb, index, middle and/or ring fingers
- 2. Nocturnal numbness** _____ (4)
Symptoms are predominantly the patient sleep; numbness wakes patient from sleep

Physical examination

- 3. Thenar atrophy and/or weakness** _____ (5)
The bulk the thenar area is reduced or where manual motor testing shows strength of grade 4 less
- 4. Positive Phalen's test** _____ (5)
Flexion of the wrist reproduces her worsened symptoms of numbness in the median nerve territory
- 5. Loss of 2 point discrimination** _____ (4.5)
Failure to discriminate 2 points held 5 mm or less apart from one another, in the median innervated digits
- 6. Positive Tinel sign** _____ (4)
Light tapping over the median nerve at the level of the carpal tunnel causing radiating paraesthesias

Total _____ (26)

>12 = 0.80 probably of carpal tunnel syndrome

>5 = 0.25 probably of carpal tunnel syndrome